

Imaging for Residents – Quiz

A 59-Year-Old Male with Right Lateral Knee Pain

Kuo-Chang Wei, Tyng-Guey Wang*

Department of Physical Medicine and Rehabilitation, National Taiwan University Hospital and National Taiwan University College of Medicine, Taipei, Taiwan

SECTION 1– QUIZ

A 59-year-old male patient complained about right lateral knee pain after he crossed his legs for meditating. The pain would appear when he bent his right knee to the terminal range of the knee and performed deep squatting. In addition, there was a tender point localized at the bony prominence of the fibular head [Figure 1]. The following ultrasound images showed the long-axis view of biceps femoris tendon and lateral collateral ligament.

WHAT IS YOUR IMPRESSION?

Financial support and sponsorship

Nil.

Conflicts of interest

There are no conflicts of interest.

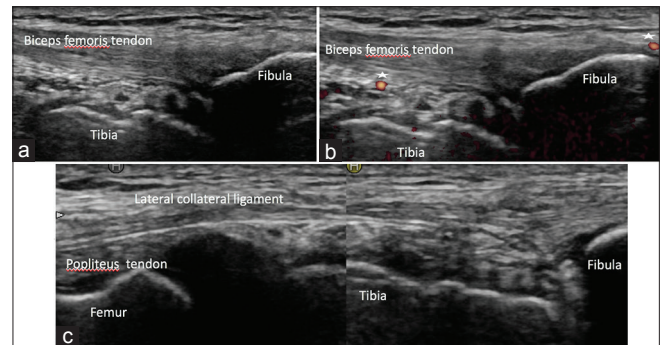


Figure 1: Ultrasound images showing long-axis view of the (a and b) biceps femoris tendon with (asterisks in image b) visible Doppler signals and (c) lateral collateral ligament

Address for correspondence: Prof. Tyng-Guey Wang,

Department of Physical Medicine and Rehabilitation, National Taiwan University Hospital and National Taiwan University College of Medicine, Taipei, Taiwan.

E-mail: tgwang@ntuh.gov.tw

Received: 22-09-2018 Accepted: 22-10-2018 Available Online: 08-01-2019

Access this article online

Quick Response Code:



Website:
www.jmuonline.org

DOI:
10.4103/JMU.JMU_92_18

This is an open access journal, and articles are distributed under the terms of the Creative Commons Attribution-NonCommercial-ShareAlike 4.0 License, which allows others to remix, tweak, and build upon the work non-commercially, as long as appropriate credit is given and the new creations are licensed under the identical terms.

For reprints contact: reprints@medknow.com

How to cite this article: Wei KC, Wang TG. A 59-year-old male with right lateral knee pain. J Med Ultrasound 2019;27:59.